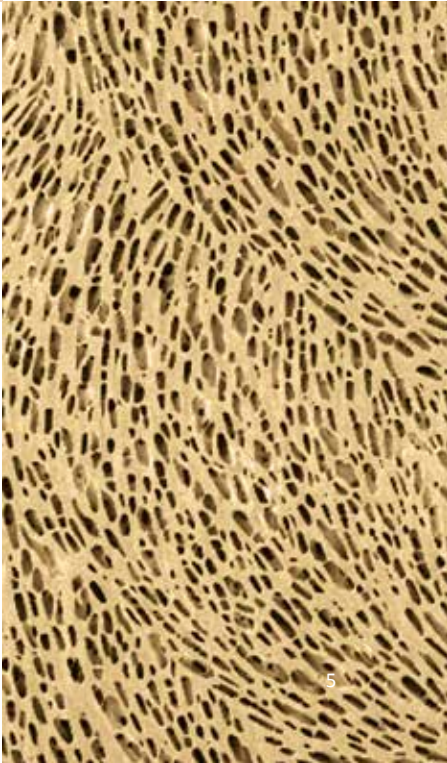

SUPRATHEL[®]

SKINN

THE **TEMPORARY** SECOND SKIN

|||PMI
The Wound Healing Company



Intelligent wound care with a temporary skin substitute

SUPRATHEL® is an innovative skin substitute indicated for the treatment of epidermal and dermal wounds. Successful use of the product has been demonstrated in the management of burns, STSG donor sites and abrasions.

Just like a second skin, SUPRATHEL® covers the wound and leads the wound through a quick, complication free healing process. SUPRATHEL® was developed analogous to the human skin and thus shares the same properties such as elasticity, permeability to water vapor and impermeability to bacteria.

SUPRATHEL® is a single application product that is applied directly to a disinfected and debrided wound bed, where it stays intact until the wound is completely healed. After it is applied, the membrane becomes translucent and makes inspection of the healing process possible.

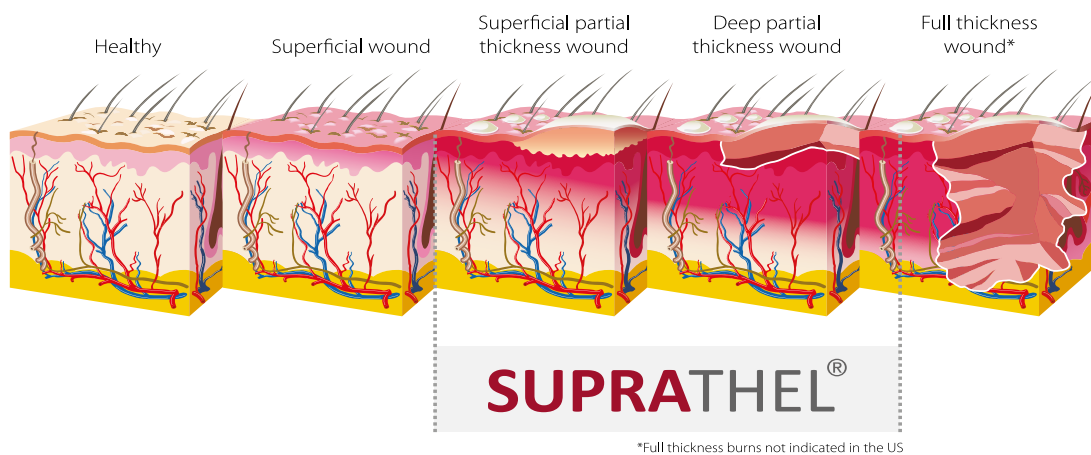
Areas of application

SUPRATHEL® was developed for the treatment of epidermal and dermal wounds. SUPRATHEL® covers a wide range of wound care:

- Burns: Partial thickness (superficial partial thickness and deep partial thickness)
- Split-thickness skin graft (STSG) donor sites
- Partial and full thickness wounds (incl. Toxic Epidermal Necrolysis (TEN))
- Large scale abrasions
- Scar revisions



Positioning in the treatment of wounds



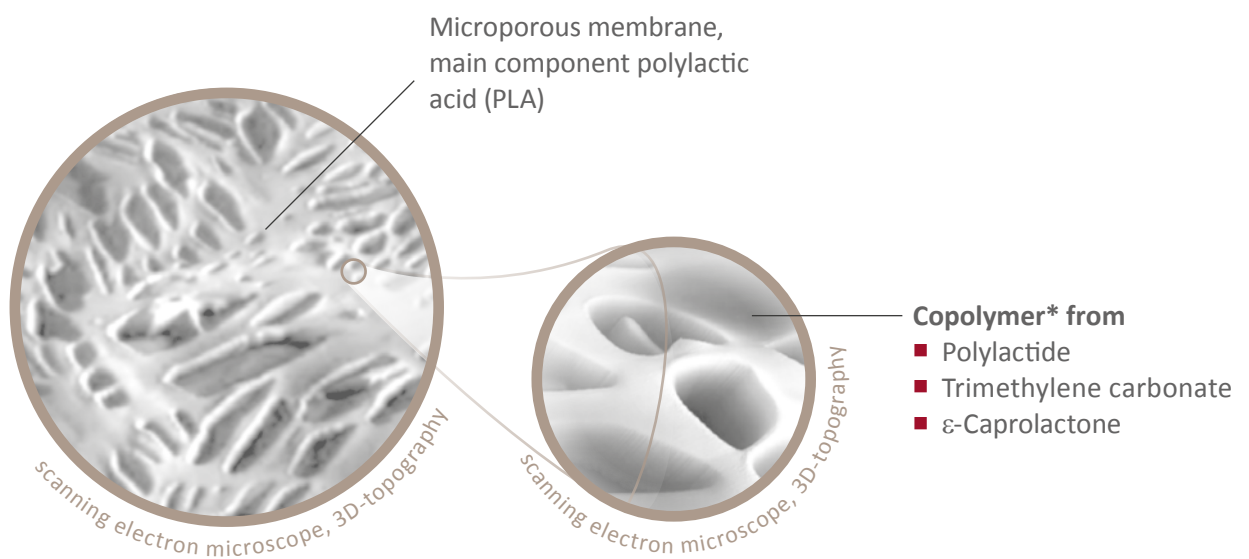
- Alginate
- Hydrofibres
- Hydrogels
- Foam dressing
- Hydrocolloids
- Film dressing

- Cadaver-based scaffolds
- STSG
- Mesh-graft transplantations
- Cultured epithelial autografts (CEA)
- Acellular grafts
- Dermal substitutes
- Xenograft

Properties

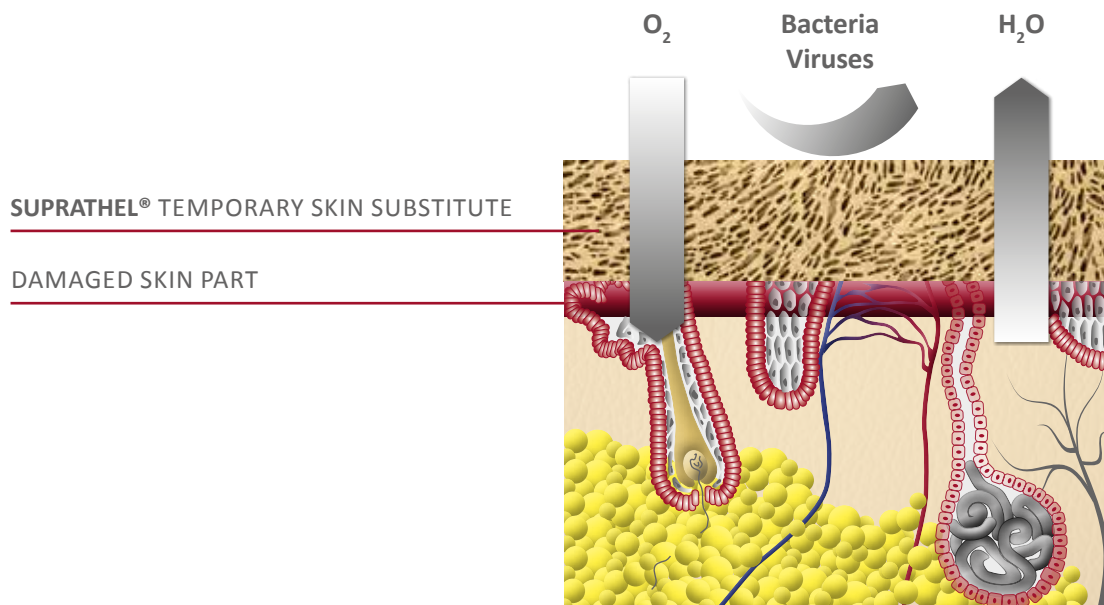
Composition	Lacto-capromer, main constituent: Polylactic acid
Degradation	4 weeks (hydrolytically)
Plasticity	> 200 % elongation at break
Permeability to water vapor	40 - 70 ml/m ² (hour) approx. 1.000 - 1.700 per day
pH	5.5 (initial) → 4.0 <i>in vitro</i>

The unique combination of strong features



* The individual components have been successfully used in surgery for decades.

SUPRATHEL® is purely synthetic and therefore does not bear any residual risks as is the case with biological products of human or animal origin.





The advantages of working with SUPRATHEL®

- **One-time application**
 - » No SUPRATHEL® dressing changes
- **Easy application and assessment**
 - » Elastic deformability, can be adjusted to all body shapes
 - » Transparent after application, allows for direct visualization
- **Significant pain relief¹**
 - » Significantly less administration of pain medication needed
 - » Significantly less dressing changes under anesthesia needed
- **No residual risks**
 - » Synthetic, biocompatible, absorbable
 - » Minimal risk of wound infection, no allergy potential
- **Quick healing process²**
 - » Less time in between uses of STSG donor sites needed
- **Excellent cosmetic results³**
- **Low treatment costs⁴**
 - » One-time application, no change of SUPRATHEL® needed
 - » Less care and aftercare needed
 - » Less need for the patient to stay in bed
 - » Less administration of pain medication needed
 - » Reduced need for use of STSG

Literature

¹ Uhlig et al., Burns 33/2007; Schwarze, Hartmann et al., Am. Plast. Surgery 60/2009; Markl et al., Am Plast. Surg. 65/2010; Highton et al., Burns 39/2013

² Uhlig et al., Burns Nov. 33/2007; Schwarze, Hartmann et al., Burns Nov. 33/2007

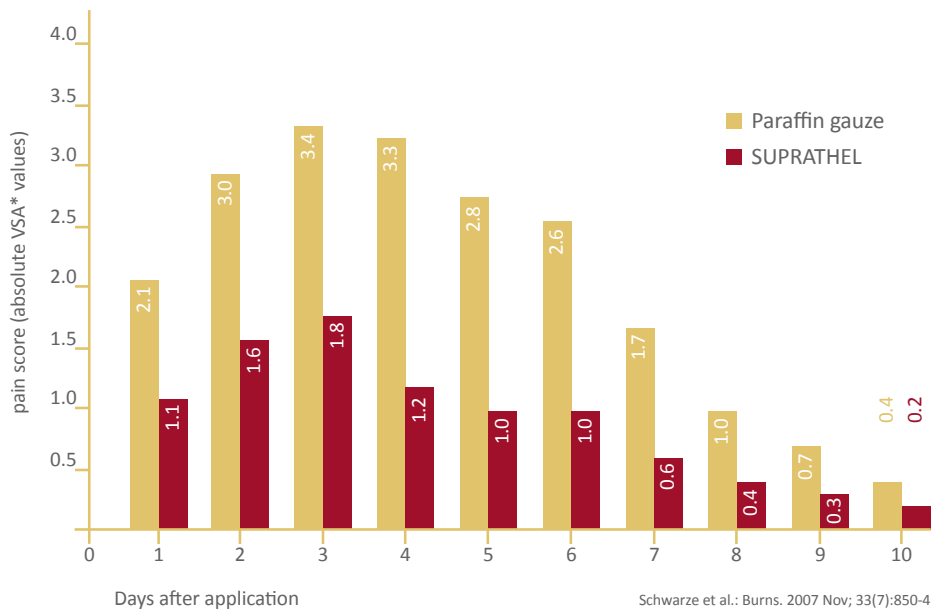
³ Uhlig et al., Burns Nov. 33/2007; Keck et al., Burns 2012 Highton et al., Burns 39/2013

⁴ Schwarze, Hartmann et al., Burns Nov. 33/2007; Everett et al., J. Wound Care 24/2015

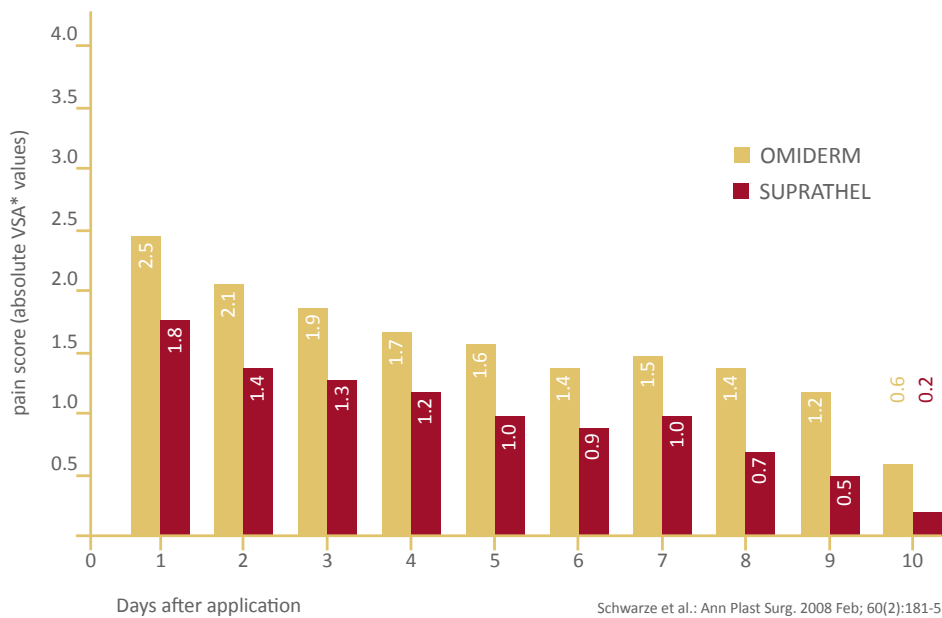


Facts and Figures

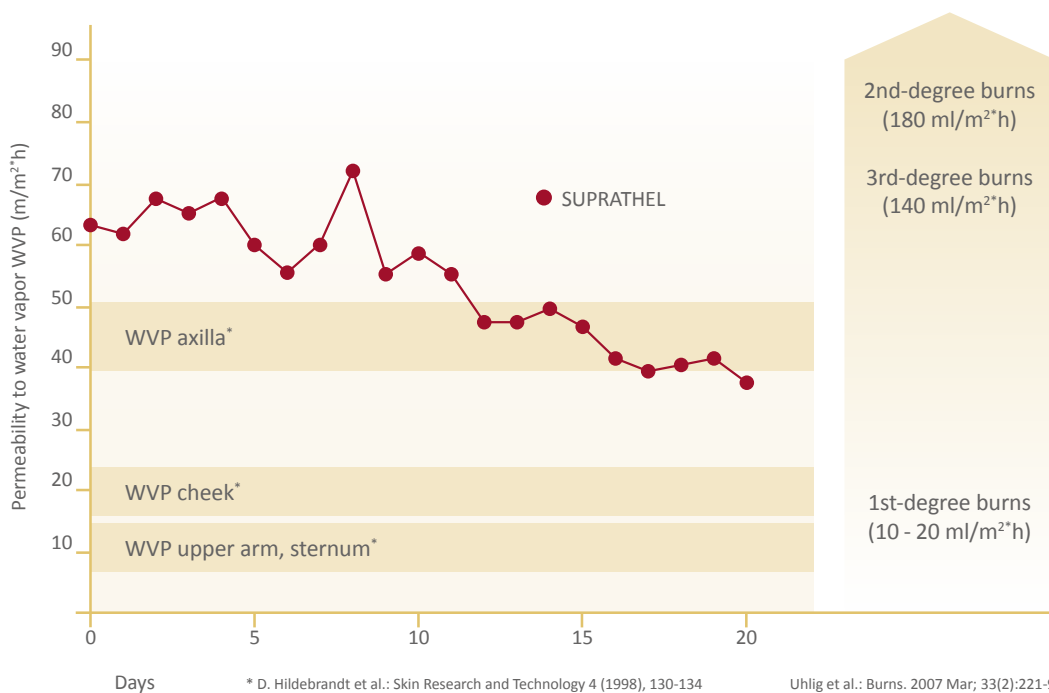
Pain relief at STSG donor sites



Pain relief in cases of burns

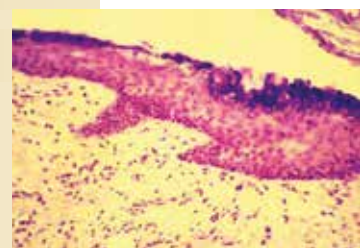
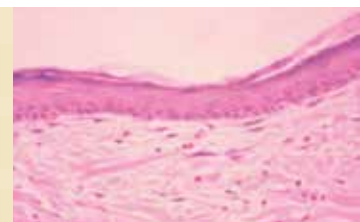


Permeability to water vapor

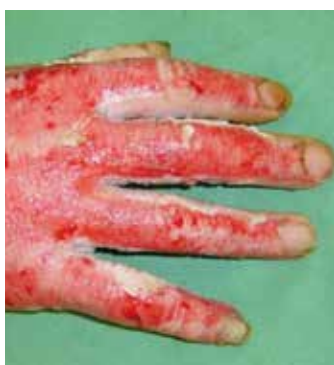

Histology

- No inflammatory response
 - Highly vascularized granulation tissue with significant capillary activity
 - Increase in extracellular matrix (ECM)
 - Increase in epithelization and building of the stratum basale
- » Superficial partial thickness: biopsy 14 days after the application of SUPRATHEL®

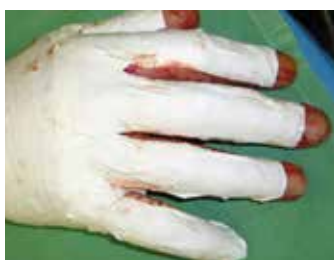

The Temporary Second Skin Application



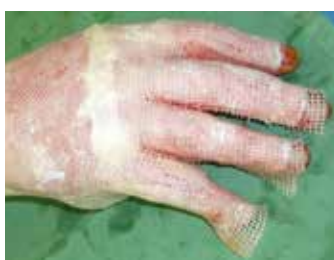Wound preparation

Complete removal of all contaminated and nonviable tissue must be performed prior to placement of SUPRATHEL®. Partial thickness and deep dermal should be thoroughly cleaned and inspected for the presence of a completely contamination free wound bed. Second degree burns require thorough debridement to ensure the absence of all contaminated and devitalized tissue.



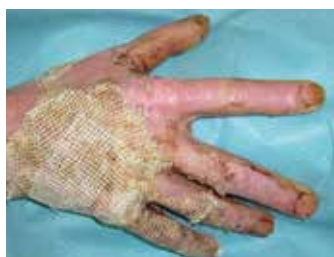Application of SUPRATHEL®

SUPRATHEL® contours well to all parts of the body. After application to the injured site the membrane becomes translucent, allowing for visualization and inspection of the healing process.



Dressing SUPRATHEL®

SUPRATHEL® should be covered with 1-2 layers of paraffin gauze which are left intact until the wound is fully healed. Only outer dressings should be changed after inspection of SUPRATHEL® or if they become soiled.

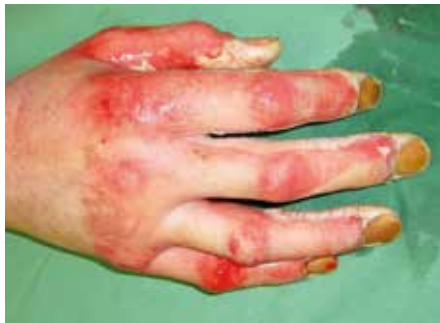

Removal of SUPRATHEL®

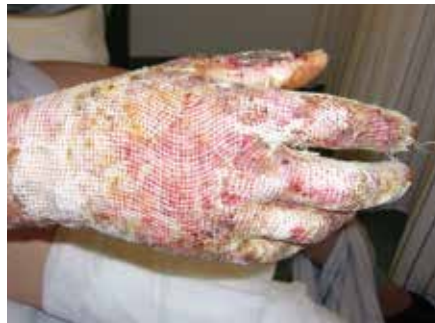SUPRATHEL® starts to detach from the skin following epithelization and may be removed without causing pain. SUPRATHEL® that is still adhering should be left on the wound.

Application with burns on the hands

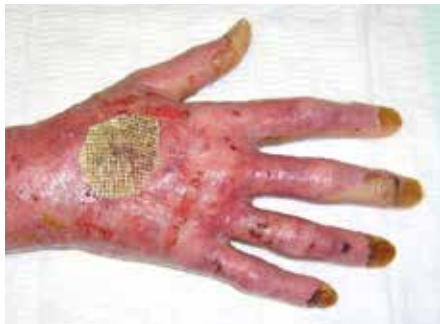59 years old, electric burns, mainly superficial partial thickness/deep partial thickness



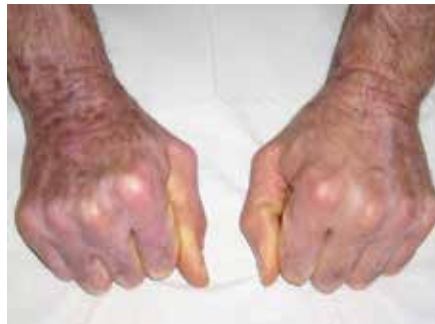» Day 1, debridement



» Day 6



» Day 21



» After 8 months

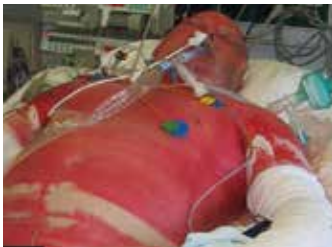Uhlig et al.: Handchir Mikrochir Plast Chir. 2007 Oct; 39(5):314-9

Advantages

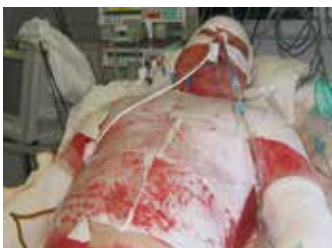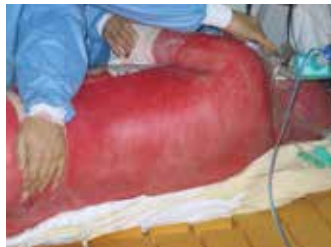Due to its excellent adhesion and flexibility it can easily be applied to difficult body parts, such as hands, fingers and toes allowing for early range of motion without disrupting the intimate contact between SUPRATHEL® and the wound bed.

Application with large scale burns

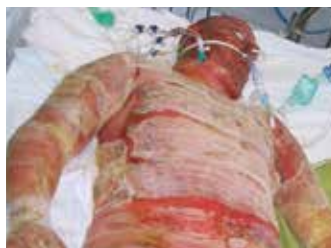38 years old, 95 % BSA, ABSI 13, mainly superficial partial thickness/deep partial thickness



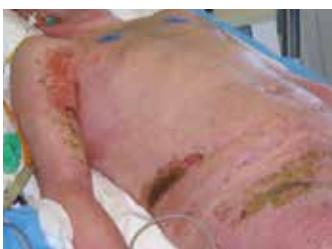» Day 2, debridement



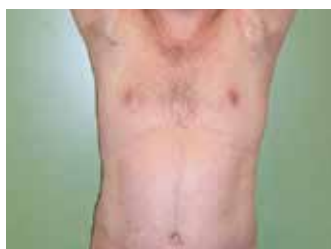» Day 2, application of SUPRATHEL®



» Day 7, SUPRATHEL® *in situ*



» 4 weeks after trauma



» 2.5 years after trauma

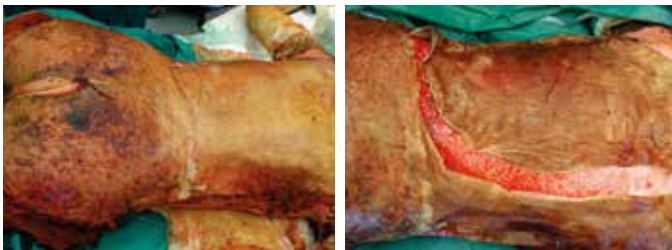Uhlig et al.: Osteo trauma care 2007; 15: 2-7

Treatment concept

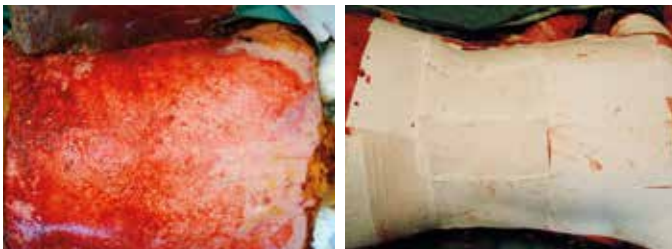
- Application of SUPRATHEL® on large areas of burned skin with various depths of burns as primary measure after surgical debridement
- Quick epithelization after a scarless healing of the burns after 8 to 14 days
- Possible second transplantation of deeper areas which are not yet healed
- Scarless healing is also possible with large scale burns

Application on partial thickness burns

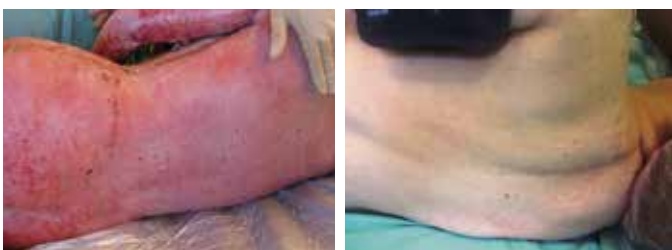36 years old, 90 % BSA, mainly deep partial thickness



» Day 0



» Day 0, debridement and application of SUPRATHEL®



» Day 18

» After 24 months

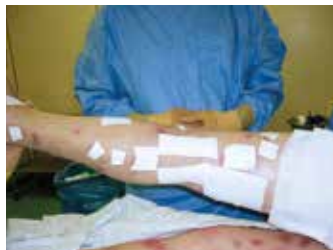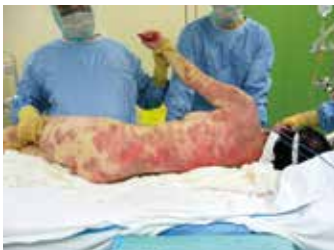Kamolz et al.: Eur Surg (2008) 40/1:19–26

Advantages

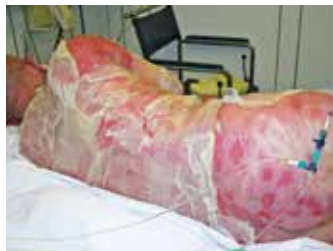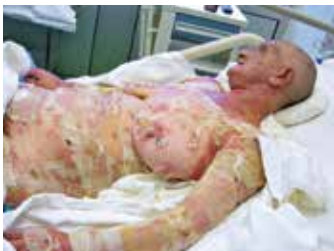- Quick epithelization of deep partial thickness burns
- SUPRATHEL® serves as primary measure for the application on large scale deep dermal burns
- Available STSG donor sites can be used for obvious full thickness degree burns
- Second transplantation after the specific identification of full thickness burns
- Almost scarless healing even with deep dermal burns

Application with TEN (Toxic Epidermal Necrolysis)/Lyell's Syndrome

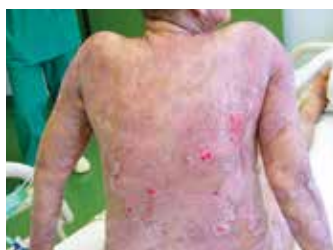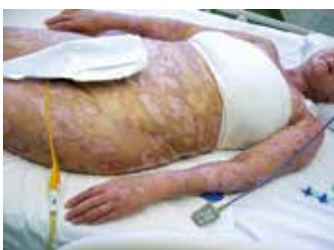48 years old, TEN (Toxic Epidermal Necrolysis), superficial partial thickness, 80 % BSA



» Day 0



» Day 6



» After 4 weeks

Uhlig, internal study, Marienhospital Stuttgart

Advantages

- SUPRATHEL® can be applied easily and safely, even to large areas
- Immediate pain relief after application
- Excellent coverage of wounds, no change of SUPRATHEL® needed
- Significantly less effort for nursing staff
- Cost reduction due to high efficiency

SUPRATHEL® packing unit

7.1 x 9.1 in / 18 x 23 cm

7.1 x 3.9 in / 18 x 10 cm

3.5 x 3.9 in / 9 x 10 cm

2.0 x 2.0 in / 5 x 5 cm

Size	Membranes	Order-No.
2.0 x 2.0 in / 5 x 5 cm	5	150505
3.5 x 3.9 in / 9 x 10 cm	1	110910
3.5 x 3.9 in / 9 x 10 cm	5	150910
7.1 x 3.9 in / 18 x 10 cm	1	111810
7.1 x 3.9 in / 18 x 10 cm	5	151810
7.1 x 9.1 in / 18 x 23 cm	1	111823
7.1 x 9.1 in / 18 x 23 cm	5	151823

Pictures show membranes in their original sizes.

Scientific publications

Beckert S et al. Lactate stimulates endothelial cell migration. *Wound Repair Regen.* 14 (2006), 321–324

Constant JS et al. Lactate elicits vascular endothelial growth factor from macrophages: a possible alternative to hypoxia. *Wound Repair Regen.* 8 (2000), 353–360

Green H, Goldberg B. Collagen and cell protein synthesis by an established mammalian fibroblast line. *Nature* 204 (1964), 347–349

Hildebrandt D et al. Electrical impedance and transepidermal water loss of healthy human skin under different conditions. *Skin Research and Technology* 4 (1998), 130–134

Hunt TK et al. Anaerobic metabolism and wound healing: an hypothesis for the initiation and cessation of collagen synthesis in wounds. *Am J Surg.* 135 (1978), 328–332

Kamolz LP, Lumenta DB, Kitzinger HB, Frey M. Tissue engineering for cutaneous wounds: an overview of current standards and possibilities. *Aktueller Stand und Möglichkeiten der Wundbehandlung durch Tissue engineering.* *Eur Surg* (2008) 40/1:19–26

Kaufman T, Eichenlaub EH, Angel MF, Levin M, Futrell JW. Topical acidification promotes healing of experimental deep partial thickness skin burns: a randomized double-blind preliminary study. *Burns Incl Therm Inj.* 12 (1985), 84–90

Klein MB, Pham H, Yalamanchi N, Chang J. Flexor tendon wound healing in vitro: the effect of lactate on tendon cell proliferation and collagen production. *J Hand Surg Am.* 26 (2001), 847–854

Lu H, Forbes RA, Verma A. Hypoxia-inducible factor 1 activation by aerobic glycolysis implicates the Warburg effect in carcinogenesis. *J Biol Chem.* 277 (2002), 23111–23115

Lu H et al. Reversible inactivation of HIF-1 prolyl hydroxylases allows cell metabolism to control basal HIF-1. *J Biol Chem.* 280 (2005), 41928–41939

Lumenta DB, Kamolz LP, Frey M. Adult burn patients with more than 60% TBSA involved-Meek and other techniques to overcome restricted skin harvest availability--the Viennese Concept. *J Burn Care Res.* 2009 Mar-Apr;30(2):231-42

Merz KM, Wissler D, Sievers R, Reichert B. Erste Erfahrungen mit Suprathel bei zweitgradig oberflächlichen Verbrennungen im Gesicht. *Plastische Chirurgie* 4/2009:213-218

Merz KM, Sievers R, Reichert B. Suprathel for coverage of superficial dermal burns of the face-Suprathel® bei zweitgradig oberflächlichen Verbrennungen im Gesicht. *GMS Verbrennungsmedizin* 2011; Vol 4, ISSN 1869-1412

Mueller E, Haim M, Petnehazy T, Acham-Roschitz B, Trop M. An innovative local treatment for staphylococcal scalded skin syndrome. *Eur J Clin Microbiol Infect Dis.* 2010 Jul;29(7):893-7

Nareika A et al. Sodium lactate increases LPS-stimulated MMP and cytokine expression in U937 histiocytes by enhancing AP-1 and NF-kappaB transcriptional activities. *Am J Physiol Endocrinol Metab.* 289 (2005), E534–542

Nolte SV, Xu W, Rodemann H-P, Rennekampff H-O. Suitability of Biomaterials for Cell Delivery in Vitro. *Osteo trauma care* 2007; 15: 42-47

Pfurtscheller K, Zobel G, Roedel S, Trop M. 2008 Dec;40(6):361-6. *Epub* 2008 Dec 2. Use of Suprathel dressing in a young infant with TEN. *Pediatr Dermatol.* 2008 Sep-Oct;25(5):541-3

Rapp, M, Uhlig C, Dittel K-K. The Treatment of Mass Burn Casualties Resulting from Mass Disaster. *Osteo trauma care* 2007; 15: 8-16

Rendl M, Mayer C, Weninger W, Tschachler E. Topically applied lactic acid increases spontaneous secretion of vascular endothelial growth factor by human reconstructed epidermis. *Br J Dermatol.* 145 (2001), 3–9

Ring A, Tilkorn D, Ottomann C, Geomelas M, Steinstraesser L, Langer S, Goertz O. Intravital monitoring of microcirculatory and angiogenic response to lactocapromer terpolymer matrix in a wound model. *Int Wound J.* 2011 Apr;8(2):112-7

Ryssel H, Germann G, Riedel K, Reichenberger M, Hellmich S, Kloeters O. Suprathel-acetic acid matrix versus acticoat and aquacel as an antiseptic dressing: an in vitro study. *Ann Plast Surg.* 2010 Oct;65(4):391-5

Ryssel H, Gazyakan E, Germann G, Hellmich S, Riedel K, Reichenberger MA, Radu CA. Antiseptic therapy with a polylacticacid-acetic acid matrix in burns. *Wound Repair Regen.* 2010 Sep-Oct;18(5):439-44

Ryssel H, Andreas Radu C, Germann G, Kloeters O, Riedel K, Otte M, Kremer T. Suprathel-antiseptic matrix: in vitro model for local antiseptic treatment? *Adv Skin Wound Care.* 2011 Feb;24(2):64-7

Schneider LA, Koerber A, Grabbe S, Dissemmond J. Influence of pH on wound-healing: a new perspective for wound-therapy? *Arch Dermatol Res* 298 (2007), 413-420

Schreml S, Szeimies RM, Karrer S, Heinlin J, Landthaler M, Babilas P. The impact of the pH value on skin integrity and cutaneous wound healing. *J Eur Acad Dermatol Venereol.* 24 (2010), 373–378

Simon A et al. Medical Honey for Wound Care- Still the 'Largest Resort'? *Evid Based Complement Alternat Med.* 6 (2009), 165–173

Schwarze H, Küntscher M, Uhlig C, Hierlemann H, Prantl L, Noack N, Hartmann B. Suprathel, a new skin substitute, in the management of donor sites of split-thickness skin grafts: results of a clinical study. *Burns.* 2007 Nov;33(7):850-4

Schwarze H, Küntscher M, Uhlig C, Hierlemann H, Prantl L, Ottomann C, Hartmann B. Suprathel, a new skin substitute, in the management of partial-thickness burn wounds: results of a clinical study. *Ann Plast Surg.* 2008 Feb;60(2):181-5

Uhlig C, Rapp M, Hartmann B, Hierlemann H, Planck H, Dittel KK . Suprathel-an innovative, resorbable skin substitute for the treatment of burn victims. *Burns.* 2007 Mar;33(2):221-9

Uhlig C, Rapp M, Dittel KK . New strategies for the treatment of thermally injured hands with regard to the epithelial substitute Suprathel. *Handchir Mikrochir Plast Chir.* 2007 Oct;39(5):314-9

Uhlig C, Hierlemann H, Dittel K-K. Actual Strategies in the Treatment of Severe Burns - Considering Modern Skin Substitutes. *Osteo trauma care* 2007; 15: 2-7

Wagner S et al. Stimulation of fibroblast proliferation by lactate-mediated oxidants. *Wound Repair Regen.* 12 (2004), 368–373

THE TEMPORARY SECOND SKIN

Polymedics Innovations Inc.

8681 Highway 92, Suite308
Woodstock, GA | USA

Phone +1 646 6042771
Fax +1 646 3503129
E-mail info@suprathel.com

www.poly-medics.com

PolyMedics Innovations GmbH

Heerweg 15 D
73770 Denkendorf | Germany

Phone +49 (0)711 719 500-0
Fax +49 (0)711 719 500-10
E-mail info@suprathel.de

